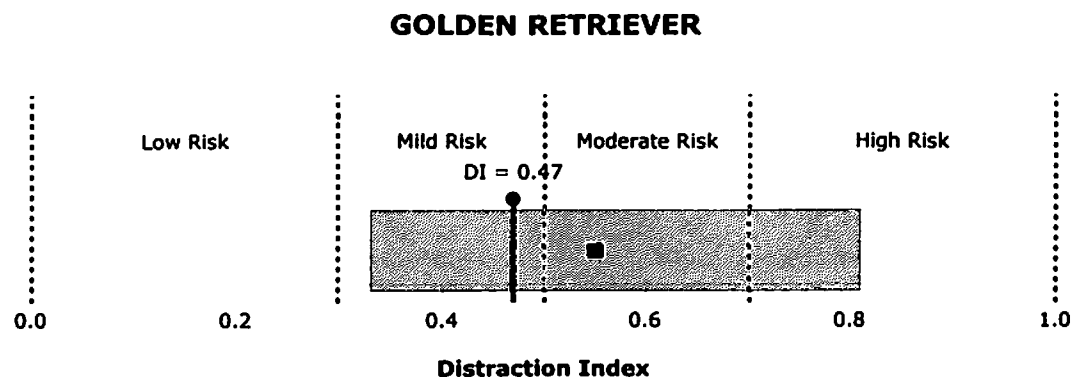


Distraction Index (DI): The laxity ranking is based on the hip with the greater laxity (larger DI). In this case the DI used is 0.47.

OA Risk Category: The DI is between 0.31 and 0.49. This patient is at mild risk for hip OA.

Distraction Index Chart:



Breed Statistics: This interpretation is based on a cross-section of 17829 canine patients of the GOLDEN RETRIEVER breed in the AIS PennHIP database. The gray strip represents the central 90% range of DIs (0.33 - 0.81) for the breed. The breed average DI is 0.55 (solid square). The patient DI is the solid circle (0.47).

Summary: The degree of laxity (DI = 0.47) falls within the central 90% range of DIs for the breed. This amount of hip laxity places the hip at a mild risk to develop hip OA. No radiographic evidence of OA for either hip.

Interpretation and Recommendations: No OA/Mild Risk: Low risk to develop radiographic evidence of hip OA early in life, however OA may manifest after 6 years of age or later. Risk of OA increases as DI, age, body weight, and activity level increase. OA susceptibility is breed specific, larger breeds being more susceptible. **Recommendations:** Evidence-based strategies to lower the risk of dogs developing hip OA or to treat those having OA fall into 5 modalities.* For detailed information, consult these documents.* Use any or all of these modalities as needed:

- 1) For acute or chronic pain prescribe NSAID PO short or long term. Amantadine can be added if response is marginal or if a neuropathic component to the pain is suspected.
- 2) Optimize body weight, keep lean, at BCS = 5/9.
- 3) Prescribe therapeutic exercise at intensities that do not precipitate lameness.
- 4) Administer polysulfated glycosaminoglycans IM or SQ, so-called DMOAD.
- 5) Feed an EPA-rich prescription diet preventatively for dogs at risk for OA or therapeutically for dogs already showing radiographic signs of OA.

At the present time there is inadequate evidence to confidently recommend any of the many other remedies to prevent or treat OA. Studies are in progress. Consider repeating radiographs at periodic intervals to determine the rate of OA progression and adjust treatment accordingly. Older dogs may show clinical signs such as chronic pain, reluctance to go stairs or jump onto the bed, and stiffness particularly after resting. It is unlikely that end-stage hip disease will develop for dogs at this risk level so surgical therapy for the pain of hip OA would rarely be indicated.

Breeding Recommendations: Please consult the PennHIP Manual.

* From WSAVA Global Pain Council: Guidelines and the 2015 AAHA/AAFP Pain Management Guidelines



*For best printing results please use Chrome or IE.
Owner's Copy

PennHIP Report

Referring Veterinarian: Dr Reid Shufer	Clinic Name: Alta Rancho Veterinary Hospital	Email: arphweb@aol.com
Clinic Address: 8677 19th St		Alta Loma, CA 91701
Fax: (909) 948-5167	Phone: (909) 980-3575	

Patient Information

Client: Bearden, Timothy	Tattoo Num:	Patient Name: Alice
Patient ID: 59891	Reg. Name:	Registration Num: SR86487702
PennHIP Num: 107352	Microchip Num: 108329819	Species: Canine
Breed: GOLDEN RETRIEVER	Date of Birth: 07 Feb 2015	Age: 27 months
Sex: Female	Weight: 65.4 lbs/29.7 kgs	Date of Study: 04 May 2017
Date Submitted: 04 May 2017	Date of Report: 07 May 2017	

Findings

Distraction Index (DI): Right DI = 0.47, Left DI = 0.38.
Osteoarthritis (OA): No radiographic evidence of OA for either hip.
Cavitation/Other Findings: None.

Interpretation